

# A Case Report on the Rare Presentation of Brucellosis-induced Spondylitis

NIVETHA MANIVANNAN RAJ<sup>1</sup>, PRIYA PERIAIAH<sup>2</sup>, SENITA SAMUEL<sup>3</sup>, VENGADAKRISHNAN KRISHNAMOORTHY<sup>4</sup>

## ABSTRACT

Human brucellosis is a zoonosis with a global distribution that can affect several organs and tissues. The most frequent brucellosis consequence, osteoarticular arthritis, has been reported in 10-85% of patients. Arthritis (most common), bursitis, tenosynovitis, sacroiliitis, spondylitis, and osteomyelitis are among the range of bone and joint disorders. The age of the patient and the *Brucella* species involved both have an impact on the type of skeletal involvement. The most common and significant clinical type of osteoarticular involvement in adults with *Brucella* species infection is spondylitis. The diagnosis of spondylitis may be challenging, and it may be made more difficult by potentially fatal neurological or vascular problems. In most cases, spinal arthritis is the most common presentation which emerges a few weeks following the initial *Brucella* infection and can impact any segment of the spine (especially lumbar region). Unlike in this case, a 54-year-old male with a history of remittent fever presented with complications where uncommon complication of sacroiliac joints are involved. Managing the infection involves a combination of antibiotics and stabilising the affected joints. Nonetheless, the therapeutic process could extend over several months, and there's a possibility of infection recurrence if not treated appropriately.

**Keywords:** Arthritis, *Brucella*, Emerging infection, Zoonosis

## CASE REPORT

A 54-year-old male, milkman by occupation, had a previous history of fever with chills, headache, nausea, myalgia and polyarthralgia for the past four months for which he was treated on and off with Cap. doxycycline 100 mg OD for various durations at various private clinics in his native. Currently, for the past three days he was on treatment with Tablet amoxicillin clavulanate 625mg twice a day and Intravenous doxycycline 100mg once daily due to the increasing intensity of the symptoms. Since the patient's condition did not improve and he developed fever, he was referred to another centre for further management. Patient presented to the referral's centre emergency department with chief complaints of fever associated with breathlessness, nausea, polyarthralgia. On physical examination he was febrile. On auscultation decreased bilateral air entry present and no other significant signs were elicited. On palpation abdomen was soft and hepatomegaly was present. No was splenomegaly. Written informed consent was obtained from the patient. During the admission, his blood picture showed normal haemogram with elevated liver enzymes [Table/Fig-1].

Routine urinalysis and Stool routine were normal. As part of the routine fever panel tests blood culture, urine culture, Enzyme Linked Immune Sorbent Assay (ELISA) for Dengue IgM, IgG, Leptospira IGM and scrub typhus IgM were performed of which scrub typhus alone was positive which was later considered as false positive. Blood culture was negative. Urine culture and sensitivity showed no growth. His peripheral smear was normal, no haemoparasites Chest X-ray and High-Resolution Computed Tomography (HRCT) thorax scan unveiled enlarged pretracheal node, bilateral subpleural parenchymal bands on lower lobes, right mild fibrosis was also noted. Considering the chronic presentations with the above given pulmonary findings, and negative blood culture the patient was started on Antitubercular therapy (T. rifampicin, T. isoniazid, T. pyrazinamide, T. ethambutol) empirically for seven days till brucellosis was identified and sputum for acid fast staining and culture for *Mycobacterium tuberculosis* were sent.

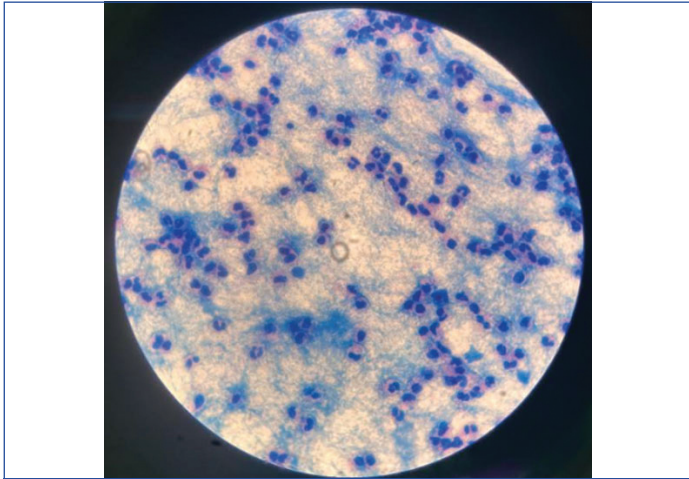
Tests	Results	Normal range
Haemoglobin (gms/dL)	13.8	12-15
Packed Cell Volume (PCV) (%)	40	36-46
Total count (cells/cumm)	5810	4000-10000
Platelets (lacs/cumm)	1.59	150000-410000
Random Blood Sugar (RBS) (mg/dL)	101	110-140
<b>Renal function test</b>		
Blood Urea Nitrogen (BUN) (mg/dL)	10	8-23
Creatinine (mg/dL)	0.9	0.72-1.18
Sodium (mmol/L)	129	136 -146
Potassium (mmol/L)	4.1	3.5-5.1
Chloride (mmol/L)	96	101-109
Bicarbonate (mmol/L)	22	22-29
<b>Liver function test</b>		
Total bilirubin (mg/dL)	1.0	0.3-1.2
Direct bilirubin (mg/dL)	0.32	<0.2
Serum Glutamic Oxaloacetic Transaminase (SGOT) (IU/L)	139	<35
Serum Glutamic Pyruvic Transaminase (SGPT) (IU/L)	99	<35
Total protein (g/dL)	7.6	6.6-8.3
Albumin (g/dL)	3.9	3.5-5.2
Globulin (g/dL)	3.6	2.0-3.5
Alkaline phosphatase (U/L)	252	30-120

**[Table/Fig-1]:** Routine blood investigations.

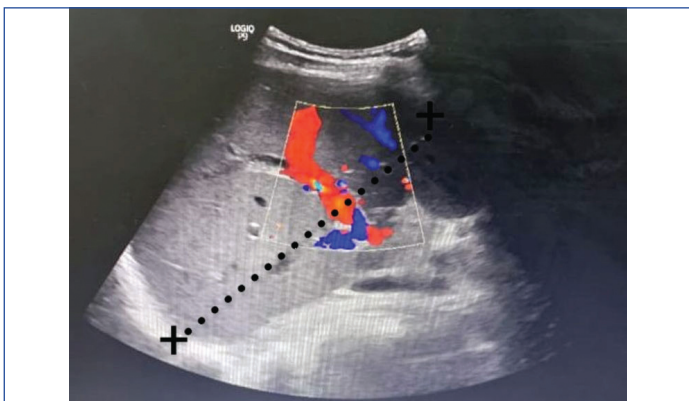
As there was no symptomatic improvement in the patient and arthritic joint pains intensified especially the back pain and the acid-fast stain for tubercle bacilli was negative [Table/Fig-2]. In view of all these findings extended blood cultures were done to rule out pyrexia of unknown origin.

Further ultrasound abdomen revealed hepatomegaly with grade 1 fatty changes and splenomegaly. X-ray pelvis revealed right sacroiliac joint spondylitis [Table/Fig-3-5]. Conventional blood culture in Bactec bottles incubated at 37°C with periodic subcultures on

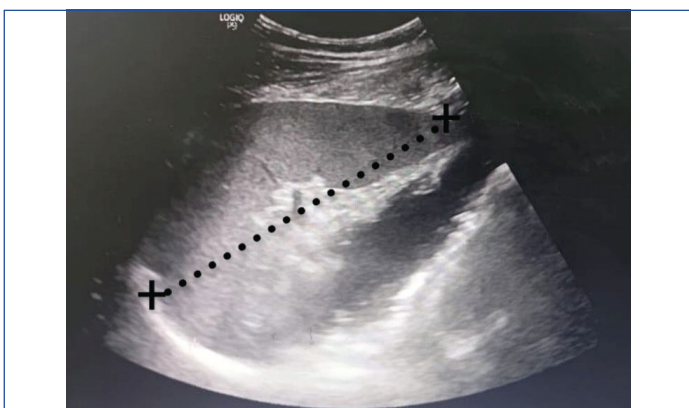
every alternative day was performed. On day 7 extended blood culture grew gram negative coccobacilli [Table/Fig-6-8] which was identified as *Brucella* spp. by Matrix Associated Laser Desorption/Ionisation (MALDI TOF) with 99.1% confidence interval and finally diagnosed as brucellar spondylitis. When furthermore history was elicited, he was found to be a milkman by occupation also consumed unpasteurised milk which was supportive to the findings. Later 16 s RNA sequencing was done and was confirmed to be *Brucella millitensis* (Accession number: OR646656).



[Table/Fig-2]: Acid fast stain of sputum sample was negative (100x magnification).

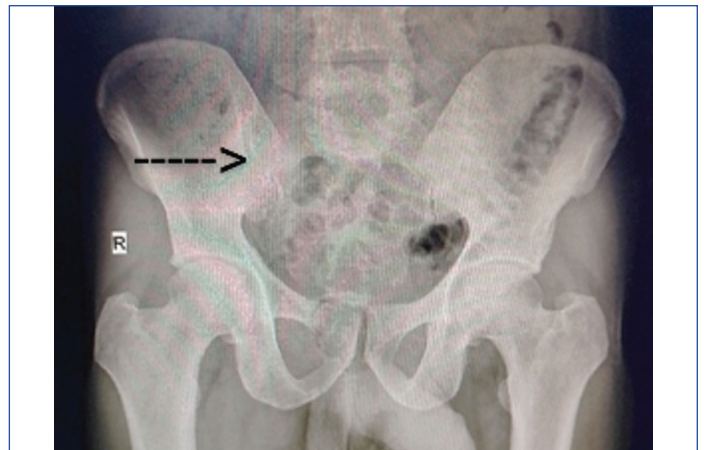


[Table/Fig-3]: USG liver: Liver enlarged (16 cm) in size with increased echotexture. No focal lesion. Biliary radicles, duct, portal vein, hepatic vein are normal.

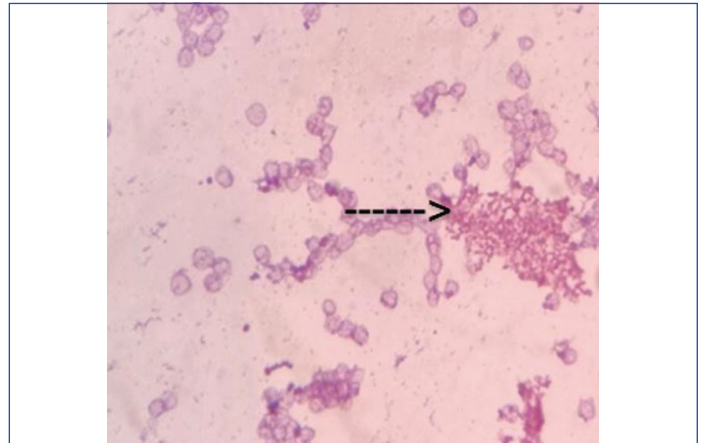


[Table/Fig-4]: USG abdomen: Spleen enlarged (14 cm) in size with normal echotexture. Splenic vein normal.

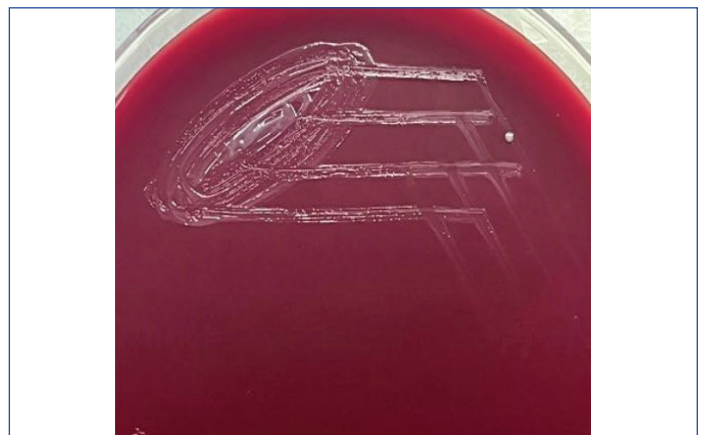In view of the clinical picture and prolonged fever patient was started on a combination of streptomycin and rifampicin. The reason for this was that similar symptoms in conditions such as melioidosis, making it a differential diagnosis. After confirmation definitive therapy was started and the patient was started on combination of Inj. streptomycin 1g twice a day and T.rifampicin 600-900 mg once daily for five days. The patient improved symptomatically and got discharged with maintenance therapy of oral Cap Doxycycline 100 mg once daily along with Tab. Rifampicin 600-900 mg once daily for



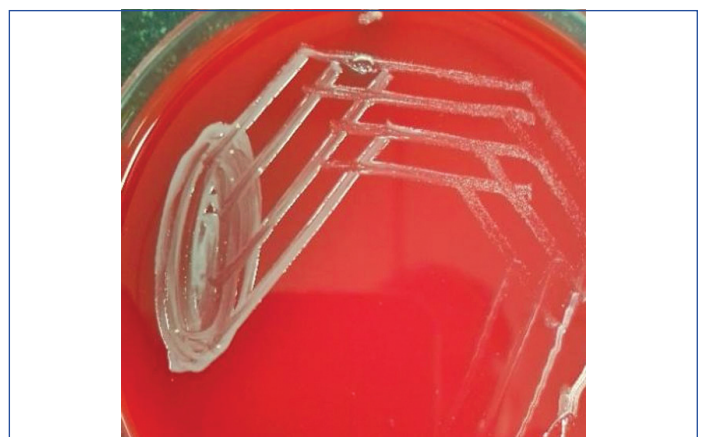[Table/Fig-5]: X-ray pelvis: The arrow indicates- Right sacro iliac joint spondylitis.



[Table/Fig-6]: Gram stain-from the blood culture with two minutes counterstain shows a group of Gram negative cocco bacilli (common presentation) under the microscope (100x magnification).



[Table/Fig-7]: Growth of *Brucella* species on blood agar after six days of incubation was small, convex, moist, translucent colony.



[Table/Fig-8]: Growth of *Brucella* species on blood agar after seven days of incubation was slightly yellow and opalescent colony.

six weeks. The patient was contacted after four months, and he had recovered from his symptoms. Repeat X-ray after six weeks was found to be improved.

## DISCUSSION

Brucellosis affects primarily animals, particularly domestic livestock such as cattle, goats, sheep, and pigs. However, it can also be transmitted to humans through direct contact with infected animals or consumption of contaminated meat and dairy products. In humans, while brucellosis is rarely fatal, it can also cause chronic illness with debilitating symptoms if not properly treated. *B. melitensis*, *B. abortus*, *B. suis*, and *B. canis* are the four *Brucella* species that cause human brucellosis [1]. As already known *Brucella* infection leads to non specific symptoms along with involvement of joints which makes it difficult to differentiate from other infectious spondylitis diseases [1]. Joint involvement can manifest as arthralgia, enthesopathy, osteomyelitis, arthritis, bursitis, tendonitis, and tenosynovitis involving the knee, hip, sacroiliac, and ankle [2]. In India the recent study in the period of 2019-2021 was by Kumari R et al., in a tertiary care centre in northern India revealed 19 (9.5%) and 23 (11.5%) positive results by anti-*Brucella* IgM ELISA and anti-*Brucella* IgG, respectively [3]. In a recent study by Khoshnood S et al., from Iran 15.53% was the estimated pooled estimate for the prevalence of brucellosis and it seems to be increasing [4].

The patient in this case visited the hospital with respiratory symptoms as one of his complaints which were commonly encountered respiratory illnesses by the physicians. This has made the physicians to overlook the significant articular symptoms which were also present as minor complaint at the time of admission making it is more challenging to diagnose brucellosis and in the process the patient's condition deteriorated. Therefore, in the differential diagnosis of back pain with fever, brucellar spondylitis should be considered. Due to the lack of specificity in its symptoms and signs, it is challenging to diagnose. Therefore, in cases with

suspicion of Brucellosis, Magnetic Resonance Imaging (MRI) blood cultures, tissue biopsies, and cultures are advised. When furthermore history was elicited from the patient, he was found to be a milkman by occupation and consumes unpasteurised milk which was a very important supportive history. Overall, brucellosis remains an important public health concern, even now in India the prevalence being around 9.9-13.3% by various methods as mentioned by Mangalgi SS et al., and is on raising trend [5]. Clinical manifestations and the isolation of *Brucella* species from blood or bone marrow cultures are required for the diagnosis of brucellosis [1].

*Brucella* responds favourably to a variety of treatment approaches. However, single-antibiotic therapy is ineffective for treating brucellosis because it results in disease relapse as well as prolonged treatment does not produce satisfactory results. In addition to providing rapid symptom relief, treatment should focus on avoiding illness relapse and future problems (such as arthritis, spondylitis, sacroiliitis, etc.). Therapy for *Brucella* infections is more successful when two antibiotics are given in combination than when used alone [6]. World Health Organisation (WHO) insists on combination therapy for Brucellosis as Monotherapy is not recommended [7]. As seen in this case patient was on doxycycline monotherapy and rifampicin as a part of empirical ATT over weeks but the patient had no clinical improvement in fact the condition of the patient continued to deteriorate. In our institute, combination therapy of streptomycin and rifampicin were started and the patient improved later he was discharged with advice of rifampicin and doxycycline combination for six weeks and asked to come for review after 15 days.

The main finding in this case was the uncommon occurrence of *Brucella* infection in the hip joint. As the symptoms of this disorder are like those of numerous other common illnesses, making early identification difficult. Various other factors should also be taken into consideration like the patient's occupational history in present case. Overview of varied literature on Brucellosis briefly in [Table/Fig-9] [2,8-11].

Author	Publication year	Place of the study	Clinical picture	Co-morbidity	Treatment	Outcome	Profession
Jahmani R et al., [2]	2021	Jordan	Fever and right hip pain	Joint effusion	Gentamicin (115 mg i.v. every 24 h), doxycycline (50 mg orally every 12 hour for 6 weeks), and rifampin (450 mg orally every 24 h for 6 weeks)	Recovered	Farmsteader
Kim EJ et al., [8]	2015	Korea	Ataxia, dysarthria, aphasia, numbness of right extremity.	Vasculitis, past h/o Brucellar spondylitis	Initial phase (1 month, inpatient): Rifampicin: 600 mg/day PO, Doxycycline: 100 mg PO, q 12h, Trimethoprim/sulfamethoxazole: 20 mg TMP/kg/day i.v., q 8 h Continuation phase (16 months, outpatient): Rifampicin: 80/400 mg PO, q 12 h, Doxycycline: 100 mg PO, q 12 h, Trimethoprim/ sulfamethoxazole: 80/400 mg PO, q 12 h	Recovered	Farmer
Chidambaram Y et al., [9]	2018	Tamil Nadu	Fever for four months, which was accompanied by myalgia, generalised exhaustion, weight loss, and appetite loss.	Hepatosplenomegaly, elevated Erythrocyte Sedimentation Rate (ESR)	Rifampicin once every day and doxycycline BD for six weeks straight.	Recovered	Professor
Dash SK et al., [10]	2022	Odisha	Abdominal pain for two months, localised to umbilical area, non radiating.	Coronary Artery Disease (CAD) post percutaneous transluminal coronary angioplasty, Post COVID pulmonary fibrosis, mild fatty liver, prostatomegaly	Rifampicin OD with doxycycline BD for six weeks	Recovered	Not mentioned
Menon DG [11]	2020	Trivandrum	Fever with night sweats for one month with weight loss	Splenomegaly	Inj. gentamicin 5mg/kg OD and doxycycline 100 mg BD for 10 days followed by C. doxyline 100mg BD + rifampin 600 mg OD for six weeks	Recovered	Dairy farmer
Present study	2024	Tamil Nadu	Fever with chills, headache, nausea, myalgia, and polyarthralgia for the past four months and fever with breathlessness, polyarthralgia	Hepatomegaly, splenomegaly	Inj. streptomycin and T. rifampicin, T.rifampicin 600-900 mg and Cap. doxycycline 100 mg for sixweeks	Recovered	Dairy farmer

[Table/Fig-9]: Summary of similar case reports along with present case.

## CONCLUSION(S)

The purpose of the article was to emphasise the importance of considering *Brucella* as one of the priority pathogens when a patient comes with fever with joint pain and the significance of initiating combination therapy to prevent further deterioration of the patient. Hence, it is for healthcare professionals to be vigilant about diagnosing and managing brucellosis to ensure timely and effective patient care.

## REFERENCES

- [1] Lee HJ, Hur JW, Lee JW, Lee SR. Brucellar spondylitis. J Korean Neurosurg Soc. 2008;44(4):277. <https://doi.org/10.3340/jkns.2008.44.4.277>.
- [2] Jahmani R, Obeidat O, Yusef D. *Brucella* septic hip arthritis: A case report. Am J Case Rep. 2021;22:e928592-1-e928592-5. <https://doi.org/10.12659/ajcr.928592>.
- [3] Kumari R, Kumar KR, Asmat J, Amita J, Kumar P, Gupta KK, et al. Human Brucellosis: An observational study from a tertiary care centre in north India. Cureus. 2023;15(8):e42980.
- [4] Khoshnood S, Pakzad R, Koupaei M, Shirani M, Araghi A, Irani GM, et al. Prevalence, diagnosis, and manifestations of brucellosis: A systematic review and meta-analysis. Frontiers in Veterinary Science. 2022;9:976215.
- [5] Mangalgi SS, Sajjan AG, Mohite ST, Kakade SV. Serological, clinical, and epidemiological profile of human brucellosis in rural India. Indian J Community Med. 2015;40(3):163-67.
- [6] Glowacka P, Zakowska D, Naylor K, Niemcewicz M, Bielawska-Drózd A. *Brucella*- virulence factors, pathogenesis and treatment. Polish J Microbiol. 2018;67(2):151-61. <https://doi.org/10.21307/pjm-2018-029>.
- [7] Young EJ. *Brucella* spp. Gillespie SH, Hawkey PM. Principles and practice of clinical bacteriology. PUBLISHER John Wiley & Sons. 2006;2:265-71.
- [8] Kim EJ, Lee SJ, Ahn EY, Ryu DG, Choi YH, Kim TH. Relapsed brucellosis presenting as neurobrucellosis with cerebral vasculitis in a patient previously diagnosed with brucellar spondylitis: A case report. Infection & Chemotherapy. 2015;47(4):268. <https://doi.org/10.3947/ic.2015.47.4.268>.
- [9] Chidambaram Y, Alagesan M, Dhas CJ. Human brucellosis in a non-susceptible host: A case report. Int J Adv Med. 2018;5(4):1072. <https://doi.org/10.18203/2349-3933.ijam20183150>.
- [10] Dash SK, Jena, L, Panigrahy R, Sahu S, Singh S. *Brucella melitensis* lurking threat in eastern part of Odisha-A case report. J Pure Appl Microbiol. 2022;16(4):2949-53. <https://doi.org/10.22207/jpam.16.4.12>.
- [11] Menon DG. A case report on Brucellosis. J Med Sci Clin Res 2020;08(07). Doi: <https://dx.doi.org/10.18535/jmscr/v8i7.94>.

### PARTICULARS OF CONTRIBUTORS:

1. Postgraduate Student, Department of Microbiology, Sri Ramachandra Medical College and Research Institute, Chennai, Tamil Nadu, India.
2. Postgraduate Student, Department of Microbiology, Sri Ramachandra Medical College and Research Institute, Chennai, Tamil Nadu, India.
3. Associate Professor, Department of Microbiology, Sri Ramachandra Medical College and Research Institute, Chennai, Tamil Nadu, India.
4. Senior Consultant, Department of General Medicine, Sri Ramachandra Medical College and Research Institute, Chennai, Tamil Nadu, India.

### NAME, ADDRESS, E-MAIL ID OF THE CORRESPONDING AUTHOR:

Dr. Nivetha Manivannan Raj,  
Department of Microbiology, Sri Ramachandra Medical College and Research  
Institute, Sriher, Porur-600116, Chennai, Tamil Nadu, India.  
E-mail: dr.rmnivetha1527@gmail.com

### AUTHOR DECLARATION:

- Financial or Other Competing Interests: None
- Was informed consent obtained from the subjects involved in the study? Yes
- For any images presented appropriate consent has been obtained from the subjects. Yes

### PLAGIARISM CHECKING METHODS: [Jain H et al.]

- Plagiarism X-checker: Oct 18, 2023
- Manual Googling: Dec 19, 2023
- iThenticate Software: Jan 23, 2024 (7%)

### ETYMOLOGY: Author Origin

### EMENDATIONS: 6

Date of Submission: **Oct 17, 2023**  
Date of Peer Review: **Nov 29, 2023**  
Date of Acceptance: **Jan 25, 2024**  
Date of Publishing: **Mar 01, 2024**